

CD Alert

National Centre for Disease Control,
Directorate General of Health Services, Government of India

July, 2021

Covid-19 Associated Mucormycosis

INTRODUCTION

Mucormycosis (previously known as zygomycosis), is a serious but rare fungal infection caused by a group of molds called mucormycetes. These fungi can be commonly found in soil and in decaying organic matter, such as leaves, or rotten wood. Mucormycosis largely affects population suffering from other health ailments or taking medicines that lower the body's ability to fight germs and illness. It most commonly affects the sinuses or the lungs after inhaling fungal spores from the air. It can also infect oral cavity or brain, gastrointestinal tract and can occur on the skin after skin injury. Important note: This is NOT "Black Fungus".

Mucormycosis occurs when a susceptible person comes in contact with its spores in the environment. This contact can happen at the skin (spores can enter through cuts, abrasions or wounds) or respiratory mucosa (through inhalation). The fungus is ubiquitous, and the spores are commonly found in the surrounding environment. This disease is not contagious and cannot be transferred from person to person or between people and animals.

Types of mucormycosis:

- Rhino-orbito-cerebral mucormycosis (ROCM)
- Pulmonary mucormycosis
- Gastrointestinal mucormycosis
- Cutaneous mucormycosis
- Disseminated mucormycosis

Box 1: Key messages

- Mucormycosis is commonly found in the environment, soil
- Mucormycosis is not black fungus, though it looks black in colour
- Risk of mucormycosis increases in people with underlying illness like diabetes

HISTORICAL BACKGROUND

Originally, mucormycosis was described by Paltauf in 1885, as an infection from nonseptate, broad, branching hyphae typical of molds. However, the first recorded human infection with Mucorales was a case of pulmonary mucormycosis reported by Sluyter in 1847.

In 1943, the syndrome of acute orbital mucormycosis characterized by uncontrolled diabetes, unilateral internal and external ophthalmoplegia, proptosis, meningoencephalitis, and rapid death was first described by Gregory.

BURDEN*

Currently India is having the second largest Covid affected population in the world with more than 2.65 crore cases as on 24th May 2021. India is also the diabetes capital of the world with nearly 7.7% of adult population being diabetic. More than 6.5 Crore people in India are diabetic (this was 2016 global burden of disease data published in lancet in 2016).

Recent times has witnessed increased cases of Mucormycosis in India. These are Covid-19 associated mucormycosis and mostly they are seen in post covid diabetic population. According to the Central government* a total of 40824 mucormycosis cases have been reported across the country out of which nearly 3229 patients have succumbed to the disease. Nearly 28186 patients are still under treatment for the same, meaning that 31% patients have been cured till date.

Very few case studies or case series have been published as of now related to Covid-19 associated mucormycosis and a review conducted in May 2021 suggested 101 cases worldwide which is only a fraction of actual cases. The article also mentions that nearly 80% are being observed in males and nearly 80% have pre-existing diabetes mellitus. The associated mortality was nearly 30%.

Reports from various states-

Recent times has witnessed increased cases of Mucormycosis in India. While the total number of mucormycosis infections is not yet known, more than 1,000 such cases has been registered till mid-May' 2021.

Twenty-three mucormycosis cases in AIIMS Delhi with 20 of them COVID-19 positive, and about 500 cases from other states. Reportedly, such cases are reported from Gujarat, Uttar Pradesh and Rajasthan too with associated mortality reported from Jabalpur in Madhya Pradesh and Thane in Maharashtra. Jabalpur reported three deaths of mucormycosis from May 1 to May 10 2021. About 10 people have lost vision while 40 others were undergoing treatment in Bhopal, Indore, Khandwa, Jabalpur, and Gwalior. From the eastern part of country, Odisha also reported its first case of COVID-19 related mucormycosis around 10 May 2021.

In Jaipur, Rajasthan; Sawai Man Singh (SMS) hospital reported 14 cases. While before COVID-19, hospital reported only one or two cases annually, in contrast to current trend of seen 2-3 cases daily with more of ocular involvement. Rajasthan State government has

declared the disease as an "Epidemic" in the State.

At least 70 cases of mucormycosis have been detected in Hyderabad in the month of April' 2021 with and at least six patients died of it from April 2021 to May 2021. In Apollo Hospitals only, around 50 such cases were reported. Telangana government has declared mucormycosis as notifiable disease under the Epidemic Diseases Act 1897.

Karnataka declared mucormycosis as a notified disease, after registering 97 cases wherein 4 patients lost their lives till 17 May 2021. A high mortality is observed in Maharashtra, where 52 patients died since COVID-19 outbreak in the state.

Recognizing the outbreak of Mucormycosis in the State, the government of Haryana has passed regulations under Section 2 of the Epidemic Diseases Act 1897. The state of Chhattisgarh also reported more than 70 such cases till mid-May 2021.

2021 Feb 16:S1473-3099(20)30784-2. doi: 10.1016/S1473-3099(20)30784-2

*Burden of Mucormycosis as on 28.06.2021

AGENT

Mucormycetes, the group of different types of fungi can cause mucormycosis. The most common causative agents are Rhizopus species and Mucor species. Other causative fungi are Lichthemia, Rhizomucor, Apophysomyces, Syncephalastrum species, Cunninghamella, etc. Belonging to the scientific order Mucorales, these mucormycetes live throughout the environment.

Humans acquire the infection predominantly by inhalation of sporangiospores, occasionally by ingestion of contaminated food or traumatic inoculation. They are more common in soil with decaying organic material, compost piles animal dung, and also present in the air.

Population at risk- All those who have lowered immunity are at an increased risk as this is an opportunistic infection. The list can include people who have the following-

- Post COVID-19 recovered population
- Elderly male population
- Uncontrolled hyperglycaemia with or without diabetes mellitus
- Malignancy (Eg: Leukaemias, Lymphomas, Aplastic anaemia, Thalassemia)
- Immunocompromised patients
- Organ transplant
- Stem cell transplant
- Iron overload (COVID-19, Bone-marrow transplantation, hemochromatosis, Therapy with iron chelators such as Desferrioxamine)
- Neutropenia, Monocytopenia
- Long-term corticosteroid use
- Intravenous drug abuse
- Skin injury due to surgery, burns, or wounds
- Prematurity and low birthweight (for neonatal gastrointestinal mucormycosis)
- Tuberculosis
- Patients living with Human immunodeficiency virus
- Chronic kidney disease
- Hepatitis-B and other Chronic Liver diseases
- Chronic alcoholics and smokers
- Cancer Chemotherapy
- Prolonged ICU stay
- Immunosuppressive therapy as part of COVID-19 treatment

CASE DEFINITION

In COVID 19 settings the most common presentation is either rhino orbital or Rhino-orbito-cerebral (ROC) Mucormycosis. The patients can be categorized as Possible (Suspected), Probable, and Proven (Confirmed).

1. A patient who has symptoms and signs of rhino-orbital or ROCM in the clinical

setting of concurrent or recently (<6 weeks) treated COVID-19, diabetes mellitus, use of systemic corticosteroids, mechanical ventilation, or supplemental oxygen to be considered as Possible ROCM.

2. A patient with clinical symptoms and signs of rhino-orbital or ROCM supported by CT scan, or contrast-enhanced MRI, diagnostic nasal endoscopy findings, the patient to be considered as Probable case.
3. A probable case with microbiological confirmation of tissue sample on direct microscopy (KOH mount) or culture or histopathology with special stains is to be taken as confirmed case.

Analysis of biological specimens from clinically involved sites is mandatory for confirmation. Every effort should be made to obtain tissue biopsies, e.g. endoscopic guided nasal tissue, aspirate, deep swab, nasal mucosal biopsy for histopathology, direct microscopy and culture. Where this is not possible, nasal scrapings can be collected for direct microscopy and culture, however this is not a very reliable sample. Debrided/resected tissue after surgery may be sent for direct microscopy, culture in normal saline and for histopathology in formalin.

Early warning signs of Mucormycosis

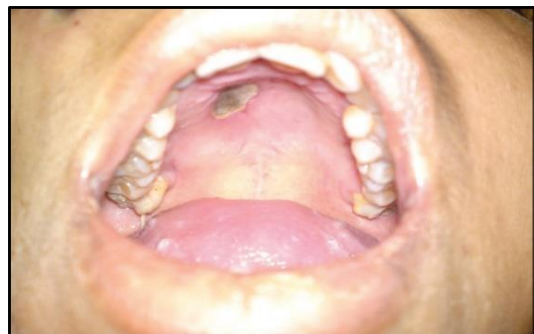

Fig:1 Brown-black necrotic patch / ulcer on palate

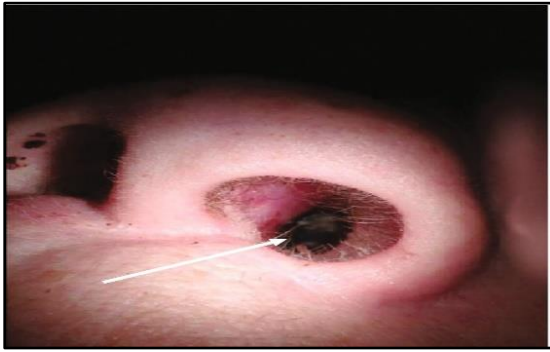


Fig:2 Brown-black necrotic patch / outgrowth in nostril

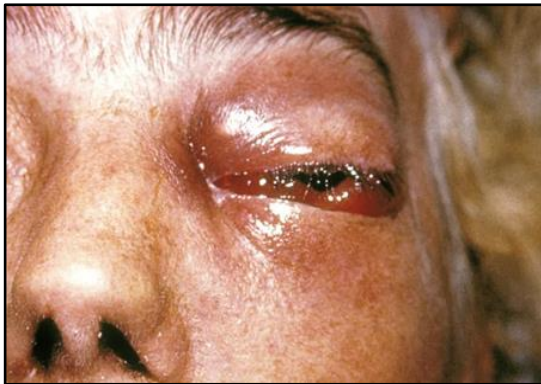

Fig: 3 Retro orbital swelling, proptosis, lacrimation

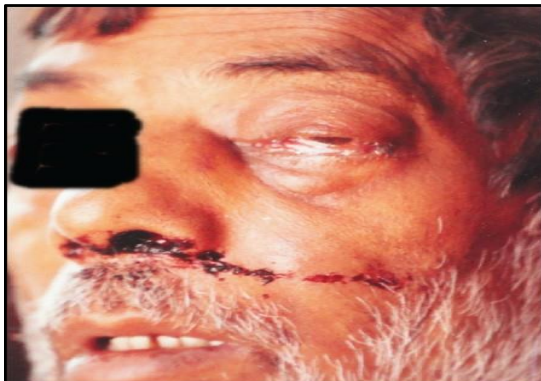

Fig:4 Blackish discharge from nose / Blood from nostril

CLINICAL FEATURES

The general early warning signs and symptoms for mucormycosis are:

- Pain and redness around eyes and/or nose (PNS)
- Fever
- Headache
- Coughing
- Shortness of breath
- Acute Haemorrhage (Epistaxis, Bleeding from the palate/gums, Hemoptysis, Blood in vomit/stools)
- Altered mental sensorium

Most common form of mucormycosis is Rhino-orbito-cerebral followed by cutaneous and pulmonary mucormycosis. In addition to the general signs and symptoms, some of the specific systemic signs and symptoms can be-

Rhino-orbito-cerebral mucormycosis

- Nasal congestion
- Nasal discharge
- Localized pain
- Facial swelling or numbness
- Headache or orbital pain
- Nasal or sinus congestion
- Toothache
- Loosening of maxillary teeth
- Jaw involvement
- Blurred or double vision with pain
- Paresthesia
- Fever

Skin lesion: thrombosis, necrosis, black lesions on nasal bridge or upper inside of mouth that quickly become more severe.

Pulmonary mucormycosis

- Chest pain
- Pleural effusion
- Hemoptysis
- Worsening of respiratory symptoms

Cutaneous mucormycosis

- Blisters or ulcers
- Black infected area with pain, redness and warmth around the wound

Gastrointestinal mucormycosis

- Abdominal pain
- Nausea and vomiting
- Gastrointestinal bleeding

Disseminated mucormycosis

- In this form, the infection spreads to other areas of the body and becomes widespread (disseminated)
- If infection is disseminated to the brain and patients can present with altered sensorium or coma
- Other areas that can be affected include the heart, kidney, spleen, skin, and other organs.

The symptoms vary according to the system being affected. If the earliest sign is orofacial pain and swelling then the patient may contact a dentist, if it is pain or pressure in the eye then the ophthalmologist is contacted, if it is fever associated with headache and nasal congestion then it is an ENT surgeon and if there is shortness of breath or chest pain then it can be a pulmonary medicine or medicine physician. Very often these patients tend to consult their family physicians first, hence it is important to educate the medical fraternity at large.

DIAGNOSIS

The finding of any of these signs should prompt immediate further testing:

Nasal Endoscopic Examination

- Black Necrotic tissue and eschar

Blood tests

- CBC (Look for neutropenia / monocytopenia, Raised ESR)
- FBS, PPBS, HBA1C
- LFT, RFT with electrolytes
- HIV, HBsAg

Radiographic imaging

- X-Ray PNS (Para Nasal Sinuses) and OPG (Ortho-Pantomogram) – can be normal
- CECT of PNS and Orbit – Erosion and thinning of hard tissues, mucosal thickening of sinuses, enlargement of masticatory muscles
- Contrast MRI – Optic neuritis, intracranial involvement, CST, Infratemporal fossa involvement
- HRCT Chest - Reverse halo sign: nodule (≤ 3 cm)/ mass (>3 cm) or consolidation with surrounding ground-glass opacity halo, central necrosis and air-crescent sign

Biopsy

Nasal cavity for ROCM, if palatal involvement then biopsy from oral cavity, Transbronchial biopsy and BAL (for Pulmonary). CT guided

FNAC can be considered in some cases of Pulmonary Mucormycosis.

Histopathology

Broad ribbon-like, thin-walled, primarily aseptate or pauci septate hyphae that have irregular diameters; with non-dichotomous irregular branching and accompanying tissue necrosis and fungal angioinvasion. (Grocott Methenamine Silver GMS and Periodic Acid-Schiff PAS stains).

Box 2: Key messages (diagnosis)

In addition to the above listed signs and symptoms, the following should be considered as red flag to initiate testing: cranial nerve palsy, diplopia, sinus pain, proptosis, periorbital swelling, orbital apex syndrome or a palatine ulcer

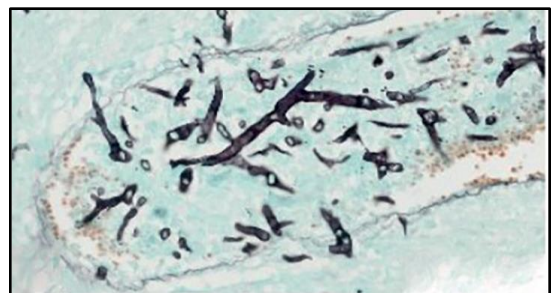


Fig: 6 GMS staining of Mucormycosis Source Lancet- MSGERC study-2019

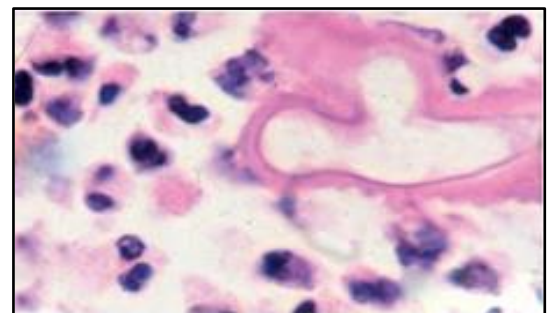


Fig: 7 H&E staining of Mucormycosis Source Lancet- MSGERC study-2019

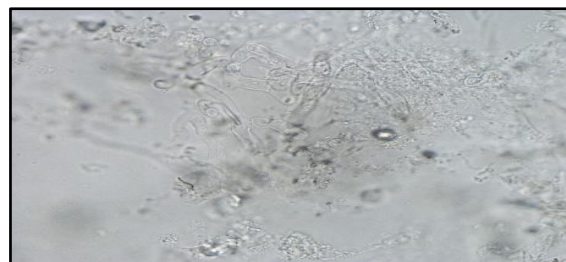


Fig: 8 KOH mount from sputum sample 1 from VPCI lab, Delhi

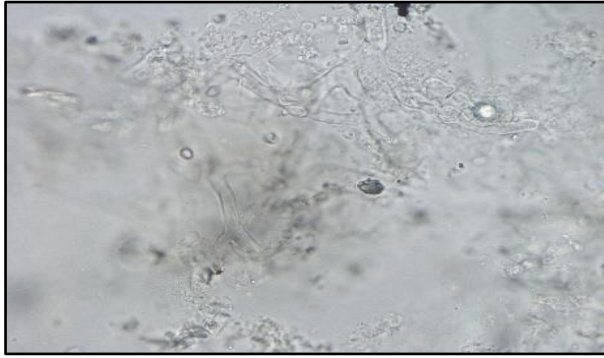


Fig: 9 KOH mount from sputum sample 2 from VPCI lab

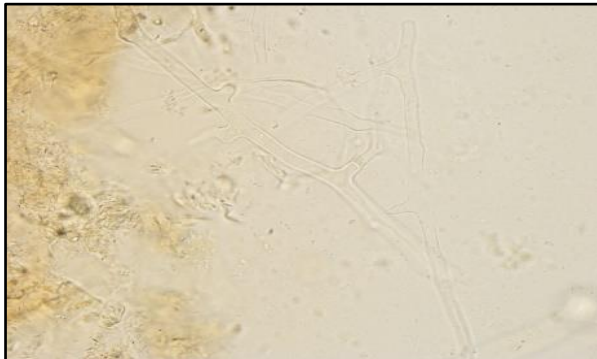


Fig: 10 KOH mount from tissue sample from VPCI lab

Direct microscopy - KOH mount (or fluorescent wet mount): an inexpensive, yet invaluable method to rapidly give a presumptive diagnosis. Mucorales are seen as broad ribbon-like, thin-walled, primarily aseptate or pauci septate hyphae that have irregular diameters; with non-dichotomous irregular branching.

Culture and sensitivity testing – Mucorales grow on any carbohydrate substrate. Colonies appear usually within 24–48 h and identification is based on colonial / microscopic morphology and growth temperature. Matrix assisted laser desorption ionization-time of flight mass spectrometry (MALDI-TOF) can be used in equipped settings. The major concern about culture, however, is its low sensitivity, as it can be falsely negative in up to 50% of mucormycosis cases. Hence a combination of clinical and laboratory work up is essential to arrive at the actual diagnosis.

Molecular methods – Molecular techniques such as PCR can be used to identify this fungus directly from the infected tissues or from bronchoalveolar lavage. However, these tests require invasive sampling (biopsy, bronchoalveolar lavage). Recently, Mucorales DNA detection in non-invasive specimens like serum have been found to be effective for early diagnosis of mucormycosis.

Serology - There are no commercially available antigen markers to detect Mucorales. β -D-glucan test and Aspergillus galactomannan tests do not detect antigen components of the Mucorales cell wall. These two tests can help to rule out invasive aspergillosis, the most frequent differential diagnosis, or combined *Aspergillus* and *Mucorales* infections.

Few additional points on Mucor and COVID-19

- Increase in ferritin level is commonly seen in COVID-19 patients. Iron overload can lead to increased susceptibility to Mucormycosis
- Prolonged use of higher end antibiotics can kill the bacterial commensals, leading to proliferation of fungal commensal such as *Rhizopus* or *Mucor* and generating a susceptible environment to cause Mucormycosis
- Excessive use of steroids can aggravate hyperglycaemia and in turn create a conducive environment for proliferation of fungi.
- Intubation, Mechanical ventilation, Chronic respiratory disease can lead to damaged epithelial and endothelial tissues – site for fungal angioinvasion
- Besides, the diffuse alveolar damage with severe inflammatory exudation, COVID-19 patients always have immunosuppression with a decrease in CD4 + T and CD8 + T cells. Severe form of COVID-19 illness is also found to reduce the level of lymphocytes as well as neutrophils. Both of which increase the chances of getting Mucormycosis infection.

PREVENTION

Use of steroids and broad-spectrum antibiotics in COVID-19, coupled with uncontrolled hyperglycaemia has found to have increased the incidence of mucormycosis. Mucormycosis can be seen in both active COVID-19 patients and in post-recovered individuals. Case fatality rates of mucormycosis according to previously reported data are as high as 50-70% and hence, prime importance should be laid on preventing the occurrence of this disease and eliminating all the risk factors leading to the infection in future. Per reports, prevalence of CAM is more among patient with diabetes. Hyperglycaemia affects the immunity and also provides favourable environment for the growth of fungi.

Primary Prevention

- Proper usage of masks (universal)
- Avoid activities that involve contact with soil or dust, such as dusting or yard work or gardening
- Hand-hygiene is a good way to avoid transferring infection from hands to the respiratory mucosa
- Proper wound care (Surgical dressing, usage of antiseptic, debridement)
- Strict glycaemic control and regular blood glucose monitoring
- Strict adherence to Anti-Diabetic medications
- Post COVID follow up and daily blood glucose monitoring in previously non-diabetics as well
- Diet and Lifestyle modifications for preventing Diabetes
- Cessation of smoking and alcohol
- Avoidance of self-medication
- Compulsory Health education to patients suffering from Covid-19 and those who have been discharged from either home isolation or facility-based treatment

- Information dissemination, Risk communication and Health education to public on early warning signs and symptoms



Fig: 11 Soil is a very important source of exposure

Secondary Prevention

- Mass chemoprophylaxis is currently not recommended
- Currently no vaccine is available for prevention of Mucormycosis
- PNS endoscopy in post COVID-19 patients who are at increased risk of development of mucormycosis (such as uncontrolled diabetics) for two months
- Judicious use of antibodies/ antifungals and steroids

Early detection of mucormycosis as well as risk factors/ associated comorbidities can help prevent severe form of disease, disability, invasive treatment and death.

MITIGATION STRATEGIES

- Stress on universal case definition, methods of diagnosis and treatment
- Continued education of treating physicians, surgeons, oral and dental surgeons, pathologists, radiologists, and microbiologists regarding mucormycosis
- An Integrate Disease Surveillance Program (IDSP) based surveillance system to identify the burden of disease in the country

- Investment on Research and Development in producing highly effective and specific pharmacotherapy

TREATMENT

The overall management of mucormycosis should be started as early as possible. Management can involve consultation with various experts like infectious disease specialist, microbiologist, histopathologist, intensivist, pulmonologist, neurologist, ENT specialist, ophthalmologist, dentist, surgeons, and radiologists. People who are suspected of having mucormycosis should contact their nearest healthcare provider at the earliest and then seek care from the above listed specialists as per the involvement of the organ.

Box 3: Basic principles of treatment

- Strict control of hyperglycaemia is vital
- Steroids are lifesaving drugs in COVID-19 patients, but abuse / misuse / untimely use must be avoided
- Judicious immunomodulating drugs
- Surgical debridement: Infected tissues are generally removed through surgical procedure at the earliest
- Monitor patients clinically, with radio-imaging for response / disease progression & microbiologically
- After 3-6 weeks of amphotericin B therapy, consolidation therapy for 3-6 months

Treatment algorithm

- The following recommendation for the treatment of CAMs is considering the evidence available
- The following algorithm is generic and should be used as a guiding tool but used judiciously by treating physicians as per the case at hand
- Special considerations must be made by the multidisciplinary treatment teams while considering extensive surgical debridement regarding future disability and quality of life of the patients
- This has been recommended by FISF in their recent guidelines specifically for treatment of Covid-19 associated mucormycosis (figure 12)
- ICMR Advisory for screening, diagnosis and management of covid-19 associated mucormycosis are at figure 13
- The guide box on managing covid-19 associated mucormycosis by DGHS are at figure 14
- The clinical guidelines from All India Institute of Medical Sciences (AIIMS), New Delhi are at figure 15.

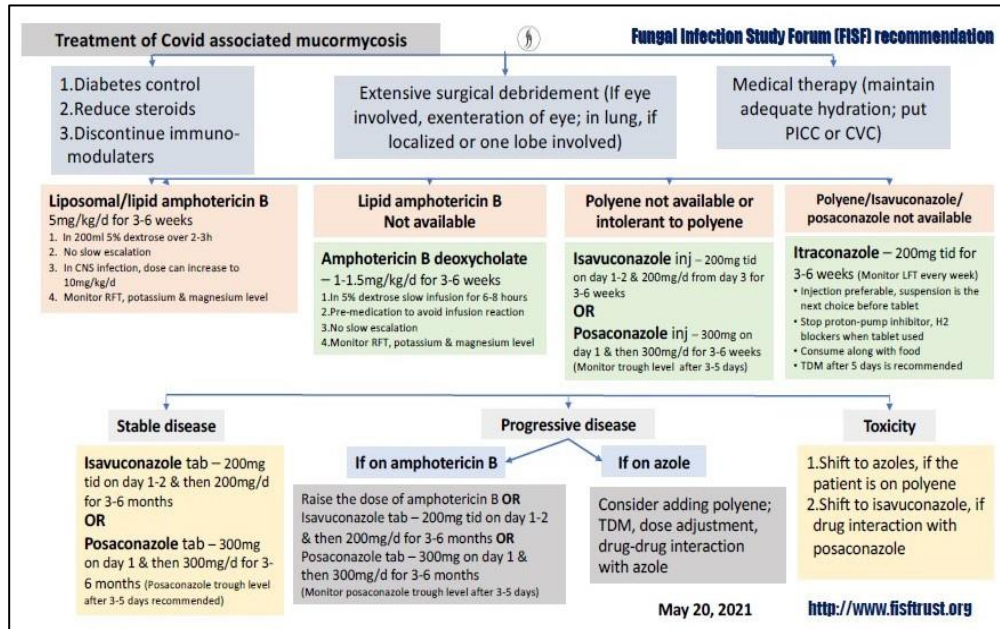



Figure 12: FISF recommendations on Treatment of Covid-19 associated mucormycosis

EVIDENCE BASED ADVISORY IN THE TIME OF COVID-19

(Screening, Diagnosis & Management of Mucormycosis)

Mucormycosis - if uncared for - may turn fatal

Mucormycosis is a fungal infection that mainly affects people who are on medication for other health problems that reduces their ability to fight environmental pathogens.



Sinuses or lungs of such individuals get affected after fungal spores are inhaled from the air.

This can lead to serious disease with warning sign and symptoms as follows:

- Pain and redness around eyes and/or nose
- Fever
- Headache
- Coughing
- Shortness of breath
- Bloody vomits
- Altered mental status

Dos

- Control hyperglycemia
- Monitor blood glucose level post COVID-19 discharge and also in diabetics
- Use steroid judiciously - correct timing, correct dose and duration
- Use clean, sterile water for humidifiers during oxygen therapy
- Use antibiotics/antifungals judiciously

Don'ts

- Do not miss warning signs and symptoms
- Do not consider all the cases with blocked nose as cases of bacterial sinusitis, particularly in the context of immunosuppression and/or COVID-19 patients on immunomodulators
- Do not hesitate to seek aggressive investigations, as appropriate (KOH staining & microscopy, culture, MALDI-TOF), for detecting fungal etiology
- Do not lose crucial time to initiate treatment for mucormycosis

Team Approach Works Best

- Microbiologist
- Internal Medicine Specialist
- Intensivist
- Neurologist
- ENT Specialist
- Ophthalmologist
- Dentist
- Surgeon (maxillofacial/plastic)
- Biochemist

Detailed management guideline & information available on the following

Global guideline for the diagnosis and management of mucormycosis, an initiative of the European Confederation of Medical Mycology in cooperation with the Mycoses Study Group Education and Research Consortium. Lancet Infect Dis. 2019 Dec;19(12):e405-e421. doi: 10.1016/j.1473-3099(19)30312-3.

https://www.ijmr.org.in/temp/indianMedRes1533311_266147_110051.pdf

https://www.ijmr.org.in/temp/indianMedRes1392195_327834_110030.pdf


Advisory developed by the following experts & National Task Force for COVID-19

<ul style="list-style-type: none"> • Dr. Anjanika Chakrabarti, Professor & Head, Department of Medical Microbiology, Chhatrapati Shivaji Maharaj Vastu Sangrahalaya, Mumbai • Dr. Anil Kumar, Infectious Disease Specialist, Immunologist • Dr. Rajeev Sonam, Consultant Infectious Disease Physician, Pune • Dr. Prakash Chandra, Vice Chairman, Critical Care, St George's Hospital, New Delhi • Dr. J. J. Joseph, Head, Department of Internal Medicine and Multidisciplinary Critical Care Management Group, St. J's Medical College & Hospital, Ahmedabad • Dr. G. Venkatesh, Dean, Government Dental College & Hospital, Ahmedabad • Dr. Saravjit Khanna, Professor, Dept. of Internal Medicine, Smt. NHL Municipal Medical College, Ahmedabad • Dr. Hemang Parikh, Medical Microbiologist, Smt. NHL Municipal Medical College, Ahmedabad • Dr. B. S. Jha, Medical Superintendent, St. Xavier's Leprosy Medical College, Hubli 	<ul style="list-style-type: none"> • Dr. Parthiv Bhatt, Professor, Dept. of Paediatrics, Pt. Deemed to be University Medical College, Raigarh • Dr. Sandeep Mishra, Associate Professor, Dept. of ENT, Chhatrapati Shivaji Maharaj Medical College, Raigarh • Dr. Chaitanya Bhatnagar, Assistant Professor, Dept. of Internal Medicine, Pt. Deemed to be University Medical College, Raigarh • Dr. Gaurav Parida, Head, Epidemiology & Communicable Disease (ECC), ICMR, New Delhi • Dr. Agnieszka Malinowska, Scientist E, Central Trial & Health Systems Research Unit, ECC, ICMR, New Delhi • Dr. Madhusudhan Das, Scientist D, ECC, ICMR, New Delhi • Dr. Tara Anand, Scientist D, Clinical Trial & Health Systems Research Unit, ECC, ICMR, New Delhi • Dr. Anand Kumar, Scientist C, Clinical Trial & Health Systems Research Unit, ECC, ICMR, New Delhi
---	--

Figure 13: Advisory from ICMR regarding COVID-19 associated Mucormycosis

Directorate General of Health Services, MoHFW, GOI

Comprehensive Guidelines for Management of COVID-19 patients



COVID-19 Management: Managing Mucormycosis guide box

What is Mucormycosis?

Mucormycosis is a fungal disease which occurs in patients with the underlying conditions and predisposing factor such as diabetes mellitus, rampant misuse/overuse of steroids, malignancies, organ transplantation etc. Mode of infection is through inhalation of fungal spores from air. It is not contagious.

Time of presentation: variable but usually around 3rd week of onset of symptoms of COVID-19.

Reasons for increase in Mucormycosis in COVID-19 patients

1. Uncontrolled hyperglycemia due to any reason
2. Misuse, overuse and irrational use of steroids.
3. Prolonged ICU stay, unhygienic humidifiers and irrational use of broad spectrum antibiotics may also be associated with mucormycosis
4. Pre-existing co-morbidities such as haematological malignancies, use of immunosuppressants, solid organ transplant etc.

Signs and symptoms:

1. Facial pain, pain over sinuses, pain in teeth and gums
2. Paraesthesia / decreased sensation over half of face.
3. Blackish discoloration of skin over nasolabial groove/ alae nasi.
4. Nasal crusting and nasal discharge which could be blackish or blood tinged.
5. Conjunctival injection or chemosis.
6. Periorbital swelling.
7. Blurring of vision/ diplopia.
8. Loosening of teeth
9. Discoloration (pale) of palate/ turbinates insensitive to touch, eschar over palate
10. Worsening of respiratory symptoms, haemoptysis, and chest pain; headache, alteration of consciousness and seizures etc

Diagnosis:

- KOH mount and microscopy, histopathology of debrided tissue (presence of Ribbon like aseptate hyphae 5-15 µ thick that branch at right angles). Culture (don't wait for results to initiate therapy as mucormycosis is an emergency).
- Relevant radiological Investigations such as CT of sinuses, CT chest for suspected pulmonary involvement (presence of more than 10 nodules, reverse halo sign, CT bronchus sign, pleural effusion-highly suggestive of mucor), MRI brain etc to see the extent of systemic involvement

Management:

- One should have a high index of suspicion of invasive fungal infection such as Mucormycosis in the presence of predisposing conditions as mentioned above. Timely initiation of treatment reduces mortality. Multidisciplinary Team approach is required. Treatment of Mucormycosis involves combination of surgical debridement and antifungal therapy.
- **Liposomal Amphotericin B** in initial dose of 5mg/kg body weight (10 mg/kg body wt in case of CNS involvement) is the treatment of choice. It should be diluted in 5% dextrose, it is incompatible with normal saline/ Ringer Lactate. It should be given over 2-3 hours and should be started with full dose from day 1. Monitoring for kidney function tests and serum electrolytes is recommended. It has to be continued till a favourable response is achieved and disease is stabilized which may take 3-6 weeks following which step down to oral Posaconazole (300 mg delayed release tablets twice a day for 1 day followed by 300 mg daily) or Isavuconazole (200 mg 1 tablet 3 times daily for 2 days followed by 200 mg daily) shall have to be taken for prolonged period as per advice of the physician..
- The therapy has to be continued until clinical resolution of signs and symptoms of infection as well as resolution of radiological signs of active disease and elimination of predisposing risk factors such as hyperglycemia, immunosuppression etc., it may have to be given for quite long periods of time.
- Conventional Amphotericin B (deoxy cholate) in the dose 1-1.5mg/kg may be used if liposomal form is not available.
- Kidney Functions must be monitored during the entire management period.

Figure 14: Clinical Guidebox from DGHS COVID-19 associated mucormycosis

All India Institute of Medical Sciences, New Delhi
Covid-19 Infection and Rhino-orbital-cerebral Mucormycosis
Treatment Organization & Guidance

ORGANIZATION OF CLINICAL SERVICES

- A multispecialty Mucormycosis Clinical team to be in place.
- To categorize patients as Covid +ve & Covid -ve. Admission as per above categorization
- Many patients with Mucor are noted to be Covid RTpcr +ve at >10 days from onset
- This may represent immunocompromise related persistence of Covid infection.

Why the surge in Mucormycosis

- COVID-19 has tendency to worsen diabetes and also precipitate diabetes in previously normal individuals
- The Covid 19 infection itself is associated with leucopenia and may lead to immune compromise caused by impaired or inappropriate immune responses.
- Immunosuppressive treatments are being widely used for treatment of Covid-19 infection .
- The severity of Mucor infection is largely dependent on the patient's immunity and general health.
- Coexistence of Covid – 19 infection with high blood sugar levels, and immunosuppressive treatments would expectedly increase incidence and severity of Mucormycosis.
- Mucor infection may occur during Covid-19 infection , or after a few weeks of apparent recovery from it.

Checklist of sentinel signs/ symptoms to be monitored in patients admitted with Covid-19

➤ **Nose and sinuses Mucor infection (relatively early disease)**
Early detection at this stage can enable early treatment and minimize complications.

- Headache and nasal obstruction- especially if persistent or severe and not responding to pain medicines.
- Nasal crusting and nasal discharge which could be brownish or blood tinged
- Pain or loss of sensation on face
- Discolouration of skin of face / localised Facial puffiness
- Loosening of teeth/ discoloration or ulceration of palate

➤ **Eye / Orbital Mucor infection (moderately advanced disease)**

- Eye swelling or redness, double vision, loss of vision, Eye pain, drooping eyelid

➤ **Intracranial infection (very advanced disease)-**

- II-VI Cranial nerve palsies (Cavernous sinus involvement) ; signs of MCA thrombosis

Treatment principles-

Urgent intervention to minimize progression and mortality/ loss of eye


- Treatment of co-morbid illness/ blood sugar control & of Covid illness
- To review Covid treatments to minimize immunocompromise
- Twice daily evaluations as per Mucor Checklist above for progression to orbital/ intracranial involvement.
- Confirmation of Diagnosis by
 - KOH Smear/ Biopsy of involved lesion with appropriate precautions.
 - Radiology – CT/ MR for assessment of disease extent.

Radiological signs in the initial phase may often be subtle and minimal and may not demonstrate florid sinusitis and bone erosion. Lack of these signs does not exclude the diagnosis

- Antifungal treatment with Amphotericin B/ Posaconazole.

In situations of high clinical suspicion consider initiation of anti-fungal chemotherapy prior to microbiological confirmation

- Early surgical debridement after stabilization of systemic illness and ensuring facilities for post surgical care/ ventilation as anticipated.



For supplementary notes visit : <https://drive.google.com/file/d/1Y8ENajpHqWsiZ3q6e6bxJNdpf54PbQSi/view?usp=sharing>

Figure 15: Clinical guidelines from All India Institute of Medical Sciences (AIIMS) on COVID-19 associated Rhino-orbital-cerebral mucormycosis

PUBLIC HEALTH SURVEILLANCE

The government has requested all the states to notify Mucormycosis through the use of a case reporting format provided on the covid portal. The IDSP district surveillance unit in coordination with the district level administration must collect the relevant data so as to capture a better picture of the disease and the factors associated with sudden apparent rise in cases.

The SOPs for reporting Mucormycosis from District/State are as follows-

- Mucormycosis a fungal infection that mainly affects people who are on medication for other health problems that reduces their ability to fight environmental pathogens. Currently, Country is witnessing an apparent rise in number of Mucormycosis cases among patients hospitalised for management of COVID-19. These cases have also been observed to have worse clinical outcomes & high mortality.
- In this context, there is a need to have a standard reporting system for Mucormycosis cases observed among confirmed COVID-19 as well as non

Confirmed COVID-19 cases from government and Private facilities managing such cases. Due to its spread & high mortality such cases are majorly being reported from tertiary care hospitals.

- Provision of daily reporting of Mucormycosis cases has been made in covid portal. District Surveillance Officer will be overall responsible of reporting Mucormycosis cases in S3 portal being managed in tertiary level Government and Private health care facilities in his/her district.
- The daily flow of information from tertiary level Government and Private health care facilities to District Health Department (DSO) and its subsequent entering in S3 portal by the DSO will be facilitated by District Magistrate/ Collector. It is extremely crucial to have a smooth flow of desired information from Medical institutions to Health Department.
- Regular sensitization meetings under the Chairmanship of DM/DC may be conducted to streamline the flow of information.

Form for Epi Data Collection (suggestive)

UNIQUE CASE ID NUMBER _____

SURVEILLANCE OF INVASIVE FUNGAL INFECTIONS IN COVID PATIENTS

GENERAL INFORMATION (in case any follow up information is required)

Name of the hospital: _____; Name of state: _____
 Name & designation of official filling the form: _____
 Phone Number _____ Email _____

PATIENT INFORMATION

Age of patient: _____ Gender of patient: _____ Occupation (rural/agriculture/urban setting): _____
 COVID positive date: _____ COVID severity: Mild/Moderate/severe
 COVID vaccination status: Complete/Incomplete (tick) Name of vaccine: _____ Date of last vaccination: _____
 Underlying risk factors (tick): Hypertension/Diabetes/Chronic Kidney Disease/Liver Disease/Hematologic malignancy/Solid organ transplant/solid organ tumour/hematopoietic stem cell transplant/CAD/Asthma/COPD/ILD/Surgery last 14 days/trauma/Blood stream infection _____
 Hospitalised for COVID: Yes/No. If yes, Number of days of admission in Ward: _____ ICU: _____
 Supplemental oxygen use: Yes/No. If yes: number of days of oxygen therapy by (specify no. of days): Nasal cannula _____/NRM/NRBM _____/NIV(BiPAP/CPAP) _____/Intubated Ventilation _____
 Lowest level of oxygen saturation: On room air: _____; On oxygen therapy: _____

COVID TREATMENT TAKEN

Type of medicine	Name of medicine	Route of admin	Dosage	No. of days taken	Previous use for other conditions
Antibiotics					
Steroids					
IL6 receptor blocker, Tocilizumab etc					
Monoclonal Ab for immune modulation					
Antivirals					
IV Ig					
JAK inhibitor					
Any other immune suppressant					
Any other					

INVASIVE FUNGAL DISEASE (IVD)

Date of presentation of symptoms suggestive of invasive fungal infection: _____; Whether developed during: COVID related admission OR after discharge; number of days after starting steroid treatment _____.
 Type of Presentation (Tick all that apply): Orbital/periorbital/Rhino/sinusitis (maxilla/sphenoid/frontal)/cerebral /bilateral/unilateral/palate/teeth/cavernous sinus thrombosis/fungal pneumonia/_____
 Diabetes mellitus status: Known Diabetic: Yes/No. If yes, no. of years since diagnosis _____. Pre-COVID HbA1C value _____; current HbA1C value: _____ Newly diagnosed diabetic: Yes/No, current HbA1C value _____.
 Blood sugar at time of presentation with IFD: _____; highest recorded blood sugar during COVID treatment: _____; episodes of ketoacidosis during COVID treatment of after: Yes/No. Cytopenia (enter values at time of IVD diagnosis or before: Neutrophil counts: _____; Lymphocyte count: _____.
 CT/MRI findings of IFD: _____
 Lab Diagnosis: Sample sent: Nasal endoscopic material OR tissue OR _____;
 Lab results: KOH: _____; Histo-path: _____; Culture: _____;
 Species identified: _____
 Treatment given for IFD: Antifungals (name, dose and duration) _____
 Surgery done: Yes/No. After how many days of IFD diagnosis _____; Procedure done: _____
 Outcome: Survived/Died (date of death) _____

References:

1. Cornely OA, Alastruey-Izquierdo A, Arenz D, Chen SC, Dannaoui E, Hochhegger B, Hoenigl M, Jensen HE, Lagrou K, Lewis RE, Mellings SC. Global guideline for the diagnosis and management of mucormycosis: an initiative of the European Confederation of Medical Mycology in cooperation with the Mycoses Study Group Education and Research Consortium. *The Lancet infectious diseases*. 2019 Dec 1;19(12):e405-21.
2. People at Risk For Mucormycosis | Mucormycosis | CDC [Internet]. 2021 [cited 2021 May 5]. Available from: <https://www.cdc.gov/fungal/diseases/mucormycosis/risk-prevention.html>
3. Petrikos G, Skiada A, Lortholary O, Roilides E, Walsh TJ, Kontoyiannis DP. Epidemiology and clinical manifestations of mucormycosis. *Clin Infect Dis Off Publ Infect Dis Soc Am*. 2012 Feb;54 Suppl 1:S23-34.
4. Roden MM, Zaoutis TE, Buchanan WL, Knudsen TA, Sarkisova TA, Schaufele RL, et al. Epidemiology and outcome of zygomycosis: a review of 929 reported cases. *Clin Infect Dis Off Publ Infect Dis Soc Am*. 2005 Sep 1;41(5):634–53.
5. Prakash H, Chakrabarti A. Global Epidemiology of Mucormycosis. *J Fungi [Internet]*. 2019 Mar 21 [cited 2021 May 5];5(1). Available from: <https://www.ncbi.nlm.nih.gov/pmc/articles/PMC6462913/>
6. Tamez-Pérez HE, Quintanilla-Flores DL, Rodríguez-Gutiérrez R, González-González JG, Tamez-Peña AL. Steroid hyperglycemia: Prevalence, early detection and therapeutic recommendations: A narrative review. *World J Diabetes*. 2015 Jul 25;6(8):1073–81.
7. Mishra GP, Mulani J. Corticosteroids for COVID-19: the search for an optimum duration of therapy. *Lancet Respir Med*. 2021 Jan 1;9(1):e8.
8. FISH recommendation mucormycosis.pdf.
9. Prakash H, Ghosh AK, Rudramurthy SM, Singh P, Xess I, Savio J, et al. A prospective multicenter study on mucormycosis in India: Epidemiology, diagnosis, and treatment. *Med Mycol*. 2019 Jun 1;57(4):395–402.
10. Jeong W, Keighley C, Wolfe R, Lee WL, Slavin MA, Kong DCM, et al. The epidemiology and clinical manifestations of mucormycosis: a systematic review and meta-analysis of case reports. *Clin Microbiol Infect Off Publ Eur Soc Clin Microbiol Infect Dis*. 2019 Jan;25(1):26–34.
11. Brunet K, Rammaert B. Mucormycosis treatment: Recommendations, latest advances, and perspectives. *J Mycol Médicale*. 2020 Sep;30(3):101007.
12. Pilmis B, Alanio A, Lortholary O, Lanternier F. Recent advances in the understanding and management of mucormycosis. *F1000Research [Internet]*. 2018 Sep 7 [cited 2021 May 17];7. Available from: <https://www.ncbi.nlm.nih.gov/pmc/articles/PMC6134337/>
13. <https://www.hindustantimes.com/india-news/cases-of-post-covid-mucormycosis-are-increasing-says-aiims-chief-101621072495151.html>
14. <https://www.msn.com/en-in/news/other/cases-of-covid-linked-mucormycosis-reported-across-india/ar-BB1gEtDV?ocid=uxbndlbing>
15. <https://www.indiatoday.in/coronavirus-outbreak/story/rajasthan-declares-black-fungus-an-epidemic-cases-accumulate-in-several-states-10-points-1804470-2021-05-19>
16. <https://www.aninews.in/news/national/general-news/telangana-declares-black-fungus-as-notifiable-disease-under-epidemic-act20210520102804/>
17. <https://www.freepressjournal.in/india/more-than-70-cases-of-mucormycosis-detected-in-chhattisgarh>
18. <https://www.theweek.in/news/india/2021/05/17/97-cases-of-mucormycosis-four-deaths-reported-in-karnataka.html>
19. <http://haryanahealth.nic.in/Documents/Mucormycosis%20notification.pdf>
20. <https://www.tribuneindia.com/news/nation/black-fungus-cases-in-maharashtra-52-dead-253035>

21. Jeong W., Keighley C., Wolfe R., Lee W.L., Slavin M.A., Kong D.C.M., Chen S.C.A. The epidemiology and clinical manifestations of mucormycosis: A systematic review and meta-analysis of case reports. Clin. Microbiol. Infect. 2019;25:26–34. doi: 10.1016/j.cmi.2018.07.011. [PubMed] [CrossRef] [Google Scholar]
22. Prakash H, Chakrabarti A. Global Epidemiology of Mucormycosis. J Fungi (Basel). 2019 Mar 21;5(1):26. doi: 10.3390/jof5010026. PMID: 30901907; PMCID: PMC6462913.
23. <https://rarediseases.org/rare-diseases/mucormycosis/>
24. Corzo-León, D.E.; Chora-Hernández, L.D.; Rodríguez-Zulueta, A.P.; Walsh, T.J. Diabetes mellitus as the major risk factor for mucormycosis in Mexico: Epidemiology, diagnosis, and outcomes of reported cases. Med. Mycol. 2018, 56, 29–43. [Google Scholar] [CrossRef]
25. Skiada, A.; Pavleas, I.; Drogari-Apiranthitou, M. Epidemiology and Diagnosis of Mucormycosis: An Update. J. Fungi 2020, 6, 265. <https://doi.org/10.3390/jof6040265>
26. Guegan H, Iriart X, Bougnoux ME, Berry A, Robert-Gangneux F, Gangneux JP. Evaluation of MucorGenius® mucorales PCR assay for the diagnosis of pulmonary mucormycosis. Journal of Infection. 2020 Aug 1;81(2):311-7.
27. Hoffmann C, Guillerme G, Le Pape P, Carausu L, Lavergne RA, Nevez G, Le Gal S. Mucorales DNA detection in serum specimens for early diagnosis of mucormycosis. Diagnostic microbiology and infectious disease. 2020 Jun 1;97(2):115004.
28. Cheng L, Li H, Li L, Liu C, Yan S, Chen H, Li Y. Ferritin in the coronavirus disease 2019 (COVID-19): A systematic review and meta-analysis. Journal of clinical laboratory analysis. 2020 Oct;34(10):e23618.
29. Sharma S, Grover M, Bhargava S, Samdani S, Kataria T. Post coronavirus disease mucormycosis: a deadly addition to the pandemic spectrum. The Journal of Laryngology & Otology. 2021 Apr 8:1-6.
30. Yang W, Cao Q, Qin L, Wang X, Cheng Z, Pan A, et al. Clinical characteristics and imaging manifestations of the 2019 novel coronavirus disease (COVID-19): a multi-center study in Wenzhou city, Zhejiang, China. J Infect. 2020. <https://doi.org/10.1016/j.jinf.2020.02.016>.
31. Donnelly, J.P.; Chen, S.C.; Kauffman, C.A.; Steinbach, W.J.; Baddley, J.W.; Verweij, P.E.; Clancy, C.J.; Wingard, J.R.; Lockhart, S.R.; Groll, A.H.; et al. Revision and Update of the Consensus Definitions of Invasive Fungal Disease From the European Organization for Research and Treatment of Cancer and the Mycoses Study Group Education and Research Consortium. Clin. Infect. Dis. 2020, 71, 1367–1376.
32. John T.M, Jacob, C.N, Kontoyiannis D.P. When Uncontrolled Diabetes Mellitus and Severe COVID-19 Converge: The Perfect Storm for Mucormycosis. J. Fungi2021,7,298.)

....about CD Alert

CDAlert is a technical bulletin of the National Centre for Disease Control (NCDC), Directorate General of Health Services, to disseminate information on various aspects of communicable diseases to medical fraternity and health administrators. The bulletin may be reproduced, in part or whole, for educational purposes.

Editorial Board

Chief Editor: Dr Sunil Kumar (DGHS)

Editorial Panel: Dr Sunil Gupta, Dr S K Singh, Dr Charu Prakash, Dr S.K.Jain, Dr Manju Bala, Dr Sandhya Kabra, Dr A Shrivastava, Dr Arti Bahl, Dr Himanshu Chauhan, Dr Simmi Tiwari, Dr Vinay Garg, Dr Rinku Sharma

Guest Editors: Dr Anuradha Chowdhary, Dr Lata Kapoor, Dr Meera Dhuria, Dr Anubhav Srivastava, Dr. Ameya Vaze, Dr. Vandana Dabla, Dr. Sudarshan, Ms. Surbhi Jain

Design and Layout: Mr. Abhishek Saini

Address: Director, National Centre for Disease Control, 22 Sharnath Marg, Delhi 110 054
Tel: 011-23971272, 23971060 Fax: 011-23922677; E-mail: dircid@nic.in
Website: www.ncdc.gov.in

Online version of NCDC CD Alert is available at NCDC website www.ncdc.gov.in